



**PATIENT**

Isabelle Levinson

**SPECIES**

Canine

**BREED**

Shih Tzu

**SEX**

Female Spayed

**AGE**

12 years

**WEIGHT**

21lbs

**PRESENTING CLINICAL SIGNS**

History: Isabelle was noted to have a heart murmur in May 2021. Has coughing fits, some of which are productive, most commonly noted after excitement or sudden movement. No labored breathing noted. Good appetite; normal activity level. On exam: NSR, grade IV/VI murmur with PMI left apical area radiating to right, PSS, lung fields clear. BP: 130mmHg x 5. No medications \*Sedated with propofol for study.

**ECHOCARDIOGRAM FINDINGS**

2D, m-mode, color flow and Doppler imaging is available.

**Left ventricle:** The LV diameter is borderline increased with hyperdynamic function. LV wall thicknesses are normal.

**Left atrium:** The left atrium is moderately dilated.

**Mitral valve:** The mitral valve is diffusely thickened with mild prolapse into the left atrial lumen. Moderate eccentric mitral regurgitation with a normal velocity.

**Aortic valve/Aorta:** The aortic valve is normal in morphology and mobility. Normal aortic outflow velocity; laminar flow. No aortic insufficiency.

**Right ventricle:** Normal right ventricular diameter and morphology.

**Right atrium:** Normal RA dimension.

**Tricuspid valve:** The tricuspid valve appears mildly thickened with trace tricuspid regurgitation. Velocity consistent with mild to moderate pulmonary hypertension.

**Pulmonic valve/Pulmonary artery:** The pulmonic valve is normal in morphology and mobility. No pulmonic insufficiency. Normal RVOT velocity; laminar flow.

**Pericardium/other:** No pericardial or pleural effusion noted. No obvious cardiac masses.

**Heart rhythm:** ECG reveals a sinus rhythm with an average HR of 160bpm.

**INTERPRETED BY**

Maggie Machen  
Lamy, DVM  
DACVIM (Cardiology)

**2-Dimensional Measurements**

Ao diam (cm)	1.4
LA diam (cm)	2.5
LA:Ao (Swe)	1.78
IVS thickness (cm)	0.9
LVID diastole (cm)	3.5
PW thickness (cm)	0.9
LVID systole (cm)	1.5
FS (%)	52

**Doppler Measurements**

PV Vmax (m/s)	0.63
AoV Vmax (m/s)	1.3
MR Vmax (m/s)	5.0
TR Vmax (m/s)	3.5
TR PG (mmHg)	50

**IMAGING**

**PERFORMED BY**

Pamela Harrigan,  
RDCS

**HOSPITAL NAME**

Mass Veterinary Services

**REFERRING VET**

Dr. Masloski

**INTERPRETATION OF THE FINDINGS**

Chronic degenerative valve disease causing moderate mitral and trace tricuspid regurgitation. Moderate left atrial enlargement indicates there is relatively low risk for imminent complication, however risk for progression to spontaneous congestive heart failure in the future is elevated. Mild to moderate pulmonary hypertension is noted, which is likely secondary to a reported cough. No additional issues are identified.

Given LA dilation, Pimobendan is recommended as below. Assessment of progression in the future will help predict long term outcome, however prognosis is guarded at this stage (B2).

The cough is suspected to be due to a combination of mainstem bronchi compression and potentially airway disease in this predisposed breed. Screening CXR, hydrocodone, etc. may be useful.

**INVOICE**

26708

**DATE**

10/4/22



**PATIENT**

Isabelle Levinson

**SPECIES**

Canine

**BREED**

Shih Tzu

**SEX**

Female Spayed

**AGE**

12 years

**WEIGHT**

21lbs

**INTERPRETED BY**

Maggie Machen Lamy, DVM  
DACVIM (Cardiology)

**IMAGING PERFORMED BY**

Pamela Harrigan, RDCS

**HOSPITAL NAME**

Mass Veterinary Services

**REFERRING VET**

Dr. Masloski

**INVOICE**

26708

**DATE**

10/4/22

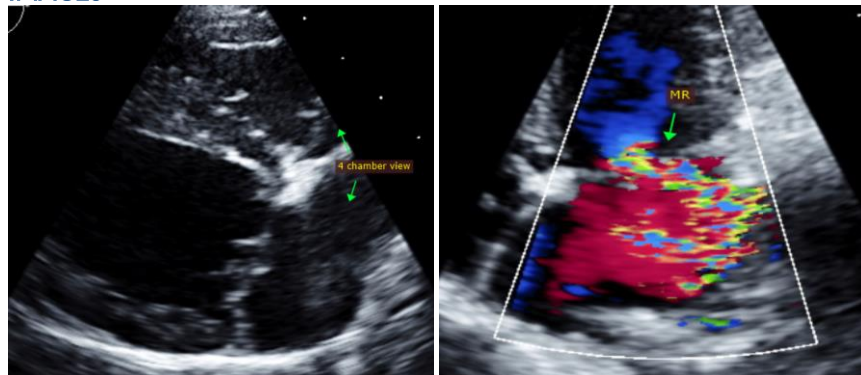
**RECOMMENDATIONS**

- Institute heart muscle support Pimobendan 0.3mg/kg PO q12h.
- Consider CXR, hydrocodone, etc. as discussed.
- Omega fatty acid supplementation and mild salt restriction may be of some long-term benefit.
- Once on Pimobendan for 3-5 days, anesthetic risk is considered mild if needed. Cardiac protective drug choices (opioid/benzodiazepine premedication, propofol or alfaxalone induction, isoflurane gas) are recommended. Pre-oxygenate for 5-10 minutes prior to induction. Monitor for arrhythmias, hypotension, and hypoxia both intra and post-operatively and intervene as necessary. Mild IV fluid restriction is recommended to avoid fluid overload. Avoid heart rate stimulating drugs such as atropine unless clinically indicated.
- Monitor for development of a cough, labored breathing, exercise intolerance or collapse episodes.

**PLAN**

- Recommend conservative monitoring with a recheck echocardiogram in 6 months, sooner if any development of clinical signs.

**IMAGES**



The information and recommendations provided are based on the images presented by the referring veterinarian. No evaluation can be communicated regarding pathology that was not visible in the image/video clips provided.

Thank you for this referral. This report was generated using transcription software, and minor dictation errors may be present. If the clinical or image interpretation does not parallel your findings or if I can be of any further assistance, please contact me.

Maggie Machen Lamy, DVM  
Diplomate of the American College of Veterinary Internal Medicine (Cardiology)  
info@sonopath.com

Echocardiogram performed by: Pamela Harrigan, RDCS  
Pet Animal Ultrasound Service (4paus.com)